OXFORD

BJS, 2021, 1–3
DOI: 10.1093/bjs/znab322
Rapid Research Communication

Purely laparoscopic explant hepatectomy and hybrid laparoscopic/robotic graft implantation in living donor liver transplantation

K. S. Suh[1,*], S. K. Hong [1], S. Lee[1], S. Y. Hong[1], S. Suh[1], E. S. Han [1], S. M. Yang[2], Y. Choi [1], N. J. Yi[1] and K. W. Lee [1]

[1]Department of Surgery, Seoul National University College of Medicine, Seoul, South Korea
[2]Department of Anaesthesiology and Pain Medicine, Seoul National University College of Medicine, Seoul, South Korea

*Correspondence to: Department of Surgery, Seoul National University College of Medicine, 101 Daehakro, Jongnogu, Seoul 03080, Korea (e-mail: kssuh2000@gmail.com)

Introduction

With the accumulation of experience in purely laparoscopic hepatectomy, including donor hepatectomy[1,2], the authors' centre initiated a minimally invasive living donor liver transplantation (LDLT) programme. Purely laparoscopic explant hepatectomy was performed in the same manner as an open technique, and the graft was implanted through an upper midline incision[3]. Successful experiences with purely laparoscopic explant hepatectomy and graft implantation using upper midline incisions have allowed extension of the minimally invasive LDLT programme to purely laparoscopic explant hepatectomy and purely laparoscopic and/or robotic graft implantation using suprapubic incisions. Initial experience of using purely laparoscopic explant hepatectomy followed by purely laparoscopic and/or robotic graft implantation is described here.

Methods

This study adhered to the Consensus-based Clinical Case Reporting Guideline Development (CARE) guidelines and was approved by the Institutional Review Board of Seoul National University Hospital (2104-190-1215).

Preoperative information relating to the donor and recipient is summarized in *Appendix S1*. Details of surgical methods are provided in *Figs 1 and 2*, *Appendix S2*, and *Video S1*.

Results

A detailed timeline of the procedure is shown in *Fig. 3*.

The weight of the native liver was 1020 g and the graft liver weighed 843 g; the actual graft-to-recipient weight ratio was 1.2. Estimated blood loss was 11 500 ml, and 20 units of red blood cells, 16 units of fresh frozen plasma, and one pack of plateletpheresis were transfused during surgery. Protocol CT on postoperative day 7 revealed no abnormal findings. The patient was discharged on postoperative day 13 (*Fig. 4*), and had experienced no major complications (Clavien–Dindo grade III or more) by 67 days after surgery.

Discussion

The safety of patients was of utmost concern during the development of this technique, and several strategies were used to manage potential catastrophic events. First, the inferior vena cava was dissected fully, and the upper side clamped temporarily with a Chitwood clamp, while the lower side was clamped with two bulldog clamps (*Fig. 1a,b*). Second, a Gelport® (Applied Medical, Rancho Santa Margarita, CA, USA) was applied to the suprapubic incision after the native liver had been retrieved and the new liver inserted (*Fig. 1b*). Hand assistance, which was not usually required in this study, was made possible through this Gelport, whenever needed.

Reconstruction of the hepatic and portal veins was performed using a purely laparoscopic approach rather than a robotic approach. The robotic approach requires docking and a large range of movements in the abdomen, and changing the patient's position after docking becomes difficult. Graft insertion and positioning of the graft for easy anastomosis are also difficult after robot docking. Moreover, docking takes time, and the hepatic and portal veins are relatively large enough to be anastomosed using the laparoscopic technique. Therefore, robot docking was performed after reperfusion. The robotic approach allowed elaborate suturing, which is required for hepatic artery and bile duct anastomosis as these structures have a small diameter.

There was significant bleeding at the site of the suprapubic incision; however, this was not identified properly during robotic procedures, but was discovered later at the end of the procedure. Several factors made it difficult to identify the source of bleeding. First, the patient was fixed in a reverse Trendelenburg position, and this could not be changed easily during the robotic procedure after robot docking. Second, the robotic arms were inserted from the caudal to the cephalic direction, and were focused on the hilar area during reconstruction of the hepatic artery and bile duct.

Received: July 23, 2021. **Accepted:** August 24, 2021

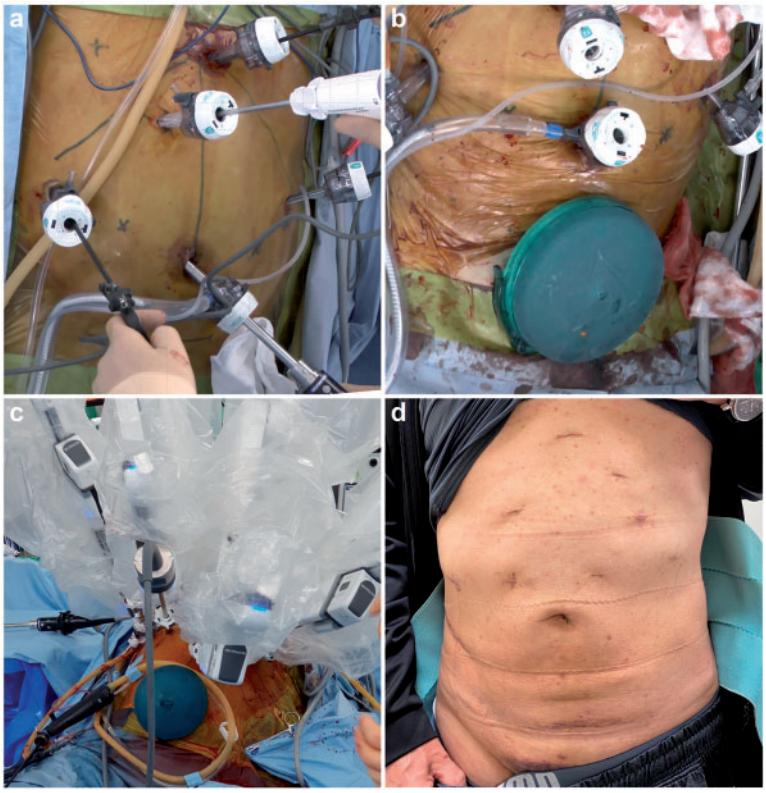

Fig. 1 Laparoscopic/robotic hybrid living donor liver transplantation

a Position of ports during purely laparoscopic explant hepatectomy, **b** position of ports and Gelport during purely laparoscopic reconstruction of hepatic vein and portal vein, **c** position of robotic arms during robotic reconstruction of hepatic artery and bile duct, and **d** abdominal wound on postoperative day 13.

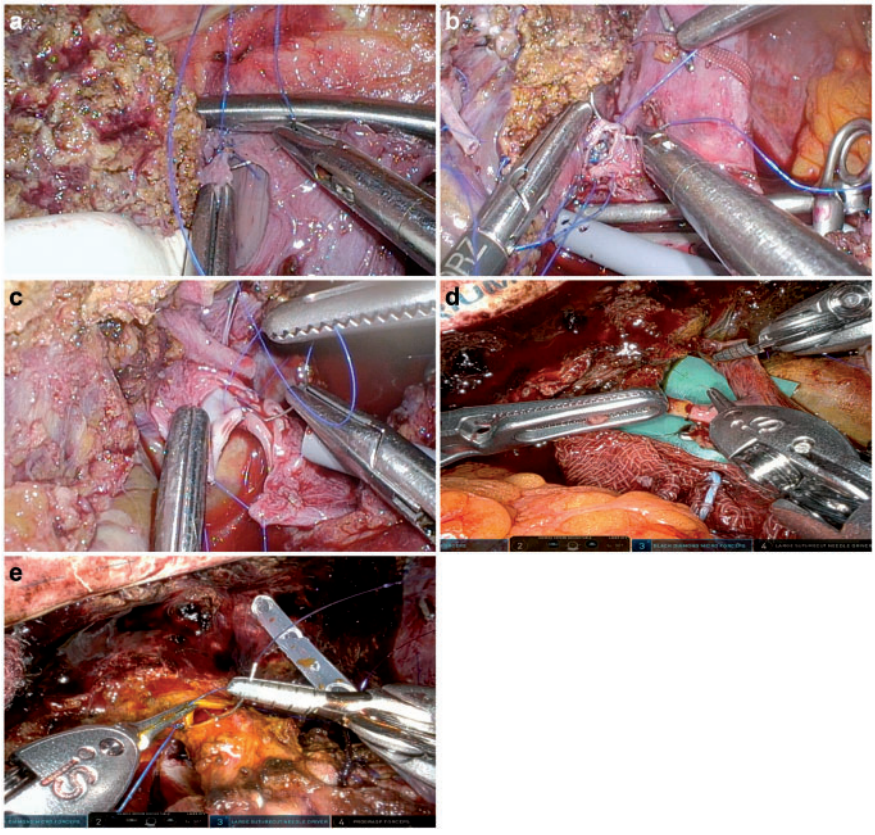

Fig. 2 Images of surgical field

a Purely laparoscopic right hepatic vein anastomosis, **b** purely laparoscopic right inferior hepatic vein anastomosis, **c** purely laparoscopic portal vein anastomosis, **d** robotic hepatic artery anastomosis, and **e** robotic bile duct anastomosis.

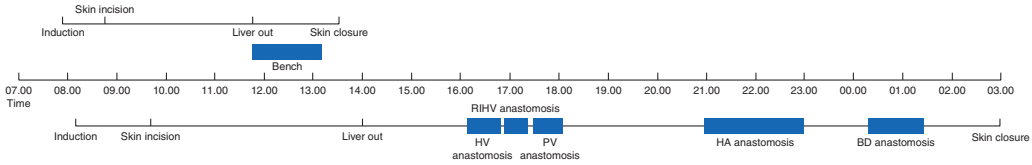

Fig. 3 Timeline of the procedure

The time taken to remove the native liver was 260 min, and the total duration of operation was 1065 min. The time required for anastomosis of the hepatic vein (HV), right inferior hepatic vein (RIHV), portal vein (PV), hepatic artery (HA), and bile duct (BD) was 41, 26, 37, 123, and 72 min respectively.

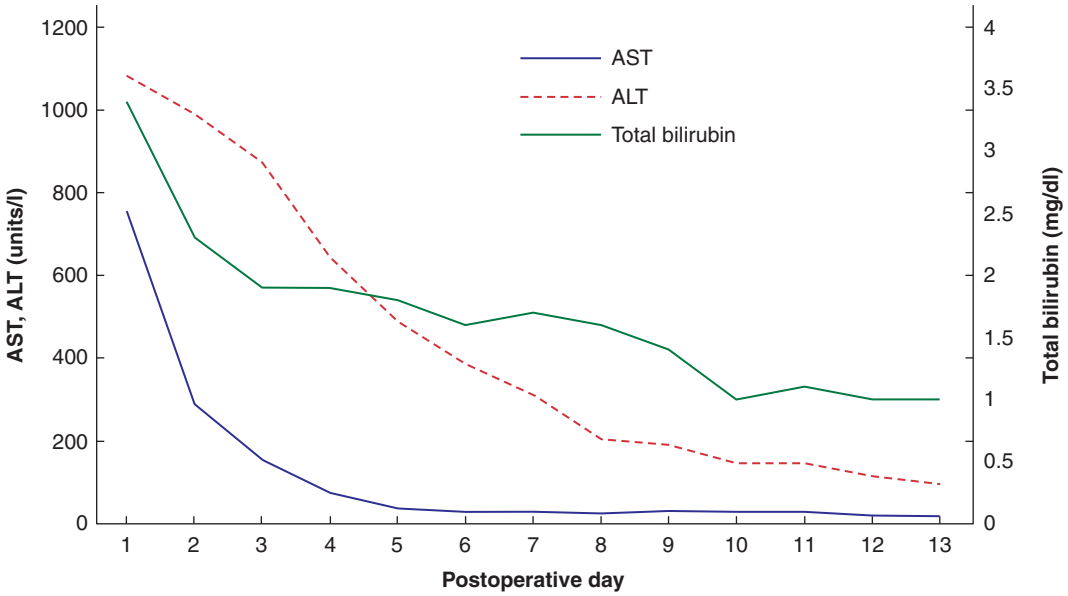

Fig. 4 Postoperative blood test results from day 1 to discharge

AST, aspartate aminotransferase; ALT, alanine aminotransferase.

The range of motion of the robotic arms, including that of the arm for the camera view, was limited; thus, haemostasis and drain insertion were performed by a purely laparoscopic approach after completion of vascular and biliary reconstruction. The success of this approach was confirmed by protocol CT on postoperative day 7, which revealed patent vascular structures without any abnormal findings.

This is the first report of a purely laparoscopic/robotic hybrid LDLT. A potential disadvantage of this procedure is the long operating time and ischaemia time, whereas a potential benefit is reduction of the size of the upper abdominal incision, which possibly reduces upper abdominal pain and enables easy lung care after operation. To evaluate the clinical benefit and safety of this procedure, more experience with additional procedures is required. Furthermore, the operating time may be reduced after overcoming the learning curve with a sufficient number of procedures. A disadvantage of robotic suturing is the lack of tactile feedback, which may result in injury, especially if the hepatic arteries are of poor quality and have small diameters. A relatively long time is also required for reconstruction of the arteries; this is due to the fixed caudal view of the robotic system, which makes visualization of the arterial lumen on the recipient's side difficult. Patient selection according to this initial experience is summarized in *Appendix S2*.

Disclosure. The authors declare no conflict of interest.

Supplementary material

Supplementary material is available at *BJS* online.

Acknowledgements

K.S.S. and S.K.H. contributed equally to this work, and are joint first authors. The data that support the findings of this study are available on request from the corresponding author.

References

1. Suh KS, Hong SK, Lee KW, Yi NJ, Kim HS, Ahn SW *et al.* Pure laparoscopic living donor hepatectomy: focus on 55 donors undergoing right hepatectomy. *Am J Transplant* 2018;**18**:434–443.
2. Hong SK, Tan MY, Worakitti L, Lee JM, Cho JH, Yi NJ *et al.* Pure laparoscopic *versus* open right hepatectomy in live liver donors: a propensity score-matched analysis. *Ann Surg* 2020; DOI: 10.1097/SLA.0000000000003914 [Epub ahead of print].
3. Suh KS, Hong SK, Hong K, Han ES, Hong SY, Suh S *et al.* Minimally invasive living donor liver transplantation: pure laparoscopic explant hepatectomy and graft implantation using upper midline incision. *Liver Transpl* 2021; DOI: 10.1002/lt.26066 [Epub ahead of print].