Video Symposium I

Left Sided Hepatectomy

Department of Surgery, Pusan National University Yangsan Hospital

Chong-Woo Chu

The patient is placed supine with the right arm extended at 90 degrees. A reversed L incision is employed. The ligamentum teres is divided. An iron intern retractor is applied to elevate the costal margins. A cholecystectomy must be carried out for leakage test and cholangiography if necessary after resection. The ligamentum teres is elevated, the hilar plate is lowered, and umbilical fissure is displayed. The left hepatic artery is easily identified once the overlying peritoneum is opened. It is ligated and divided. Dissection at the base of umbilical fissure exposes the left portal vein. It is ligated above the origin of caudate branch. The coronary ligament is dissected till exposing the middle and left hepatic vein. If the lesion is not cancer, the left triangulat ligament is also dissected and the left lateral segment is lifted and turned to the right. The gastrohepatic ligament is completely divided. The ligamentum venosum is identified and divided close to its entry into the left hepatic vein. The left and middle hepatic veins are easily encircled after dividing of the ligamentum venosum. After interrupting the blood supply and mobilizing the left lobe, ultrasound is used to confirm the resection line in relation to the middle hepatic vein and a safety margin. The liver surface is marked along the line of resection using an electrocautery. Traction sutures are applied at both sides 1 cm apart from resection line. Dissection of the parenchyma is performed along the segment boundary with the CUSA (Cavitron Ultrasonic Surgical Aspirator). It is carried out to about 5 cm depth under traction with manually pulling both sided traction sutures. A dual traction method is applied subsequently (Figure). Both sided traction sutures are pulled latero-caudally and fixed with the tower clips (A). And then, parencymal dissection plane is took down caudally and opened widely. Widely opened dissection plane is more widen with manual traction (B). Parenchymal dissection is more easily and safely carried out with this dual traction method. Smaller vessels are closed with clips, larger ones with fine atraumatic sutures. Resection follows the previously designed line exposing the middle hepatic vein. The left bile duct is transected with clamping the remnant bile duct. If the lesion is cancer, the left lobe is fully mobilized at that time. The left hepatic vein can be easily identified and securely transected with the endo-GIA stapler. A specimen is finally out after that procedure. The clamped remnant bile duct is opened and probed to check margin and the orifice of it is closed with 6-0 polyprophylene suture. Any bile leak on the resected surface can then be identified by injecting blue dye mixed saline into the cystic duct and secured. Two closed drains are usually placed on the resection plane.

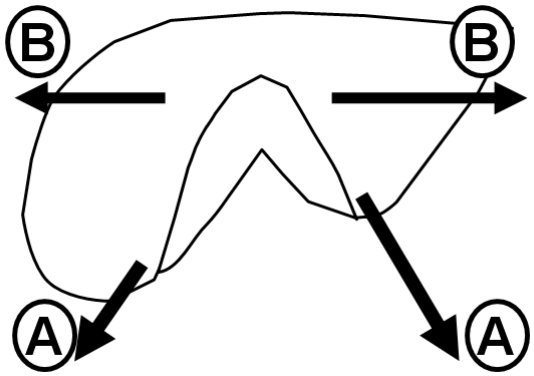

Fig. 1. Dual Traction Method. Both sided traction sutures are pulled latero-caudally and fixed with the tower clips (A). Widely opened dissection plane is more widen with manual traction (B).