MIS in pediatric HBP surgery

Hyun-Young Kim
Seoul National University, Korea

The major impact of minimal invasive surgery onto modern surgery had been that surgeons are now thinking in terms of invasiveness. As a result open surgery has evolved as well and there is a tendency to avoid large incisions.

The smaller the exposure, the less stress response and the more difficult to prove that the endoscopic surgical variant is superior.[1]

It leaves no doubt that minimal invasive surgery in its broad sense is going to develop further. Pediatric surgeons should be able to provide their patients with the best available treatment options, including the endoscopic surgical approach.

Since its first application in pediatric surgery in 1971[2], laparoscopic surgery has become increasingly popular to the point of becoming the treatment of choice in many disease entities. The range of diseases for which children can receive laparoscopic surgery is also becoming more diverse.

MIS in pediatric HBP surgery

Jones et al.[3] performed the web based world-wide survey for delineate the current status of MIS in pediatric surgery in 2008. The survey was mailed out to 390 pediatric surgeons whose e-mail addresses were available and the response rate was 38.2%.

The summary of the current status as detailed in Table 1.

In pediatric HBP surgery, several diseases can be performed in selected cases.

According to the world wide survey, the pediatric surgeons recommend laparoscopic cholecystectomy in 99%, laparoscopic Choledochal cyst excision in 28%, laparoscopic kasai procedure for Biliary atresia in 17%, laparoscopic liver resection for Liver tumor in 16%.

Table 1 Current recommendations for pediatric MIS

No.	Condition	Perform MIS	Recommend MIS	Not indicated [n (%)]	Total responses
1	Inguinal hernia	14	7	95 (82)	116
2	Undescended testis	24	9	83 (72)	116
3	Nonpalpable testis	82	26	8 (7)	116
4	Simple appendicitis	81	21	14 (12)	116
5	Complicated appendicitis	63	13	40 (35)	116
6	Exploration—abdominal pain	76	31	8 (7)	115
7	Ovarian torsion	76	30	9 (8)	116
8	Reduction of intussusception	27	22	67 (58)	116
9	Bowel resection anastomosis	30	24	62 (53)	116
10	Gastrostomy	64	22	30 (26)	116
11	Fundoplication	70	33	12 (10)	116
12	Pyloromyotomy	34	13	69 (59)	116
13	Adhesiolysis	52	22	42 (36)	116
14	Correction of malrotation	21	24	68 (60)	113
15	Cholecystectomy	93	21	1 (1)	115
16	Splenectomy	72	28	15 (13)	115
17	Adrenalectomy	43	53	18 (16)	114
18	Nephrectomy—dysplasia	45	50	17 (15)	112
19	Nephrectomy—Wilms' tumor	5	10	97 (87)	112
20	Heminephrectomy	22	36	50 (46)	108
21	Choledochal cyst	8	24	81 (72)	113
22	Biliary atresia	3	16	95 (83)	114
23	Liver tumors	3	15	95 (84)	113
24	Hirschsprung's—biopsies	64	31	20 (17)	115
25	Hirschsprung's—pull-through	60	31	24 (21)	115
26	Anorectal malformations	38	37	38 (34)	113
27	Pyeloplasty	12	47	45 (43)	104
28	Reimplantation of ureters	4	30	66 (66)	100
29	Bladder/ureteric stone	18	51	32 (32)	101
30	Varicocele correction	48	37	25 (23)	110
31	Achalasia cardia correction	48	41	24 (21)	113
32	Hiatal hernia repair	56	37	18 (16)	111
33	Lung resection	41	42	28 (25)	111
34	Treatment of empyema	71	31	11 (10)	113
35	Diaphragmatic hernia repair	23	25	63 (57)	111
36	Tracheoesophageal fistula repair	8	28	75 (68)	111
37	Mediastinal lesions	29	51	28 (26)	108

Laparoscopic liver surgery

Minimal invasive liver resection has not gained wide popularity because of the fear for intraoperative complications such as bleeding and gas embolism[1]. However, improvements in laparoscopic technology and increased experience now authorize laparoscopic liver resection in selected pediatric patients. Anterior and left lateral resections (segment 2-6), including left lateral lobectomy are selected indications for laparoscopic pediatric liver surgery.

Laparoscopic kasai portoenterostomy for biliary atresia

Since the laparoscopic kasai portoenterostomy was first introduced by Esteves et al[4] in 2002, many reports have been published showing the advantages of the minimally invasive surgery for BA[5,6]. The well illuminated and magnified vision, a good visualization of the portal structures can be obtained. Postoperative pain, breathing difficulty, and adhesion can be avoided after laparoscopic operation[7]. In experienced hands, laparoscopic kasai portoenterotomy is effective in achieving good bile drainage although more patient data with longer follow up are required to see if this is comparable if not superior to conventional open surgery.

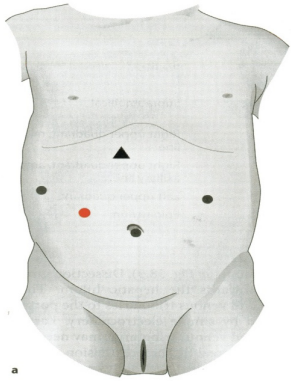

Cannulae

Cannula	Method of insertion	Diameter (mm)	Device	Position
1	Closed	5, Step	Laparoscope initially, working instruments later	Supraumbilical
2	Closed	5, Step	Laparoscope later on	Right upper quadrant, midaxillary line
3	Closed	5, Step	Working instruments	Right upper quadrant, anterior axillary line
4	Closed	5, Step	Assistant's grasper, suction	Left upper quadrant
5	Closed	No cannula	Optional, Nathanson	Epigastrium

Laparoscopic excision of choledochal cyst

Laparoscopic treatment is feasible in the treatment of choledochal cysts. Ever since Farello's publication[8] on Laparoscopic choledochal cyst excision, the procedure has gained great popularity around the world and become an effective alternative treatment to its open counterpart. Not only is Laparoscopic choledochal cyst excision safe and effective, but it also has several advantages over its open counterpart including excellent visualization, shorter recovery time, prevention of adhesion, less pain and obviation of long subcostal incisions[9,10]

Cannulae

Cannula	Method of insertion	Diameter (mm)	Device	Position
1	Closed	5, Step	Laparoscope initially, working instruments later	Supraumbilical
2	Closed	5, Step	Laparoscope later on	Right upper quadrant, midclavicular line
3	Closed	5, Step	Working instruments	Right upper quadrant
4	Closed	5, Step	Assistant's instruments	Left upper quadrant
5	Closed	No cannula	Nathanson retractor	Epigastrium

References

1. Bax et al. Endoscopic surgery in infants and children. 2008(eds) p3-5
2. Canlorbe P, Borniche P, Chartier M. Indications of celioscopy in pediatric gynecology. Ann Pediatr (Paris)

1971, 18(10):589-592.
3. Jones VS, Cohen RC. Two decades of minimally invasive pediatric surgery-taking stock. J Pediatr Surg. 2008 Sep;43(9):1653-9.
4. Esteves E, Clemente Neto E, Ottaiano Neto M, et al. Laparoscopic Kasai portoenterostomy for biliary atresia. Pediatr Surg Int 2002;18(8): 737-40.
5. Matinez-Ferro M, Esteves E, Laje P. Laparoscopic treatment of biliary atresia and choledochal cyst. Semin Pediatr Surg 2005;14:206-15.
6. Aspelund G, Ling SC, Ng V, et al. A role for laparoscopic approach in the treatment of biliary atresia and choledochal cysts. J Pediatr Surg 2007;42:869-72.
7. Liem NT, Son TN, Quynh TA, Hoa NP. Early outcomes of laparoscopic surgery for biliary atresia. J Pediatr Surg. 2010 Aug;45(8):1665-7.
8. Farello GA, Cerofolini A, Rebonato M et al. Congenital choledochal cyst: video-guided laparoscopic treatment. Surg Laparosc Endosc. 1995 Oct;5(5):354-8.
9. Liem NT, Pham HD, Vu HM. Is the laparoscopic operation as safe as open operation for choledochal cyst in children? J Laparoendosc Adv Surg Tech A 2011; 21: 367-70.
10. Hong L, Wu Y, Yan Z et al. Laparoscopic surgery for choledochal cyst in children: a case review of 31 patients. Eur J Pediatr Surg 2008; 18: 67-71.